

## EVALUATING RADIOGRAPHIC HEART SIZE USING VHS AND VLAS

### The value of assessment of cardiac size

We've all had clients who could not afford a complete cardiac workup for their coughing dog or simply a dog or cat with a heart murmur. The patient's caregivers may pay for the physical examination, blood work and radiographs, but they just can't pay the cost of a specialist consultation and an echocardiogram. This can put a lot of pressure on the general practitioner to determine if a heart problem is serious enough for treatment.

Thoracic radiographs are the most important tool in differentiating congestive heart failure (CHF) from other conditions such as respiratory disease. Thoracic radiographs can also be used to decide if heart failure prevention therapy is indicated. However, a general practitioner may be faced with evaluating radiographs from different dog breeds of differing body size and morphology (for example, a dachshund, a chihuahua and a Great Dane) and needs be able to tell if the patient has an enlarged heart. For some breeds, this can be a real challenge.

To address this dilemma, Drs. James W. Buchanan and Jorg Bücheler at the University of Pennsylvania developed the **Vertebral Heart Size (VHS)** —sometimes called vertebral heart scale or score— to assist veterinarians in the assessment of overall heart size. The VHS is a method that allows veterinarians to evaluate the heart size across dog breeds based on comparison to the patient's own vertebral body length. There is a good correlation between heart size and vertebral body length, and normalizing the cardiac measurements to the patient's body size provides an accurate assessment of true cardiac enlargement. Later work identified the utility of using the same technique of comparing cardiac measurements to vertebral body length to establish Vertebral Left Atrial Size (VLAS) as an indicator of left-sided heart enlargement in dogs.

The VHS measurement can also be an effective tool in cats. Several studies have established the normal range for feline VHS (Litster and Buchanan 2000, Ghadiri et al 2008). In contrast to dogs, VHS in cats can be measured in either lateral or ventrodorsal (VD) projections.

## The value of measuring the Vertebral Heart Size (VHS)

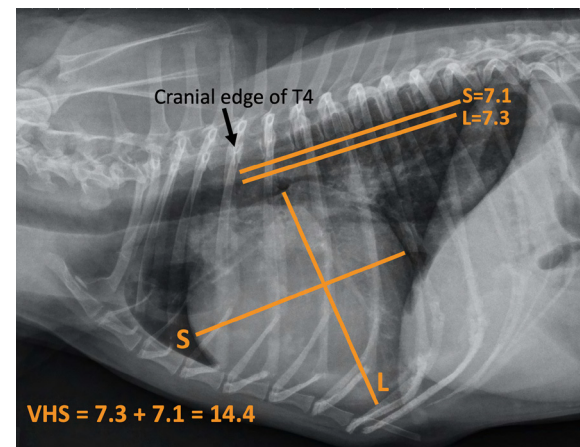
- Radiographic interpretations can be subjective, but the VHS allows the veterinarian to make an objective measurement of heart size.
- The VHS is a useful measurement regardless of whether the patient has a wide or deep thorax, is male or female or whether the radiograph was taken in a right or left lateral recumbency.
- Vertebral body size tends to correlate nicely with body size in dogs. No matter how big the dog, if its vertebral heart size ends up being more than 10.5 vertebral bodies, the heart is likely enlarged.
- The VHS is something that veterinarians can teach their technicians to do. The technician can look at the radiograph and do a VHS before bringing it to the veterinarian for evaluation. There are even commonly used radiographic viewers that have an automatic VHS function in which the computer uses artificial intelligence to calculate the VHS.

*Step by step directions for assessment of VHS in dogs and cats appear in Boxes 1 and 2, and Figures 1, 2 and 3.*

### BOX 1

#### MEASURING VHS IN DOGS

1. Take a lateral radiograph of the thorax, centered over the heart.
2. Measure the long axis of the cardiac silhouette as the length (L) from cardiac base (ventral margin of the carina) to cardiac apex, and the short axis width of the heart (S), perpendicular to the length measurement, typically at the ventral margin of the caudal vena cava.
3. Compare L and S lengths to the spinal vertebrae beginning with the fourth vertebral body on the spine (T4).
4. Count how many vertebral bodies the length (L) of the heart covers and add number of vertebral bodies covered by the width (S) measurement. A vertebral body consists of the vertebral body starting at the cranial end-plate and includes the disc space immediately caudal to that vertebra. Determine the length of each individual line to the nearest 0.1 thoracic vertebra.
5. VHS is expressed as the sum of L + S measured in vertebral-body units. If the sum of these two measurements is greater than 10.5, the dog probably has an enlarged heart. VHS in normal dogs tends to fall within a range of 8.4 to 10.5.

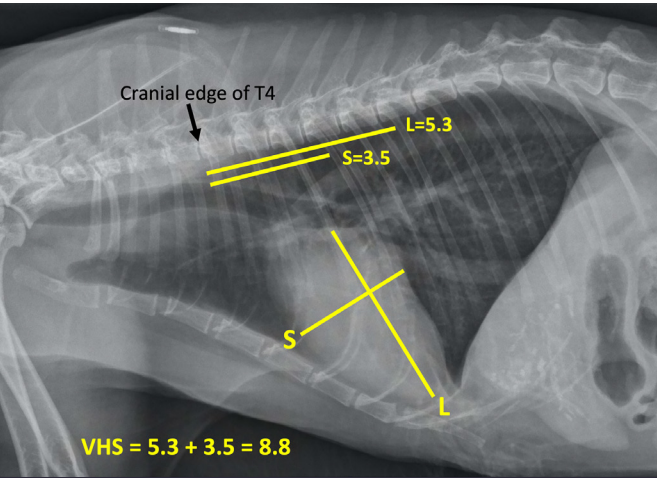


**Figure 1:** VHS measurement in a dog, left lateral view. Measurement of cardiac silhouette in long axis (L) and short axis (S), with comparison of L and S to vertebral body lengths.

# MEASURING VHS IN CATS (LATERAL VIEW)

## Using the lateral projection:

1. Identify the long axis of the heart (L) beginning at the point where the pulmonary vein crosses the trachea and ending at the apex of the heart.
2. Place another line perpendicular to the long axis at the widest point of the cardiac silhouette to estimate the short axis (S) measurement.
3. Identify the 4th thoracic vertebra (T4), and place lines equal in length to the L and S lines at the cranial edge of T4.
4. Determine the length of each line to the nearest 0.1 thoracic vertebra and add these two measurements for a VHS.
5. Normal right lateral VHS in a cat is 6.9 to 8.1.

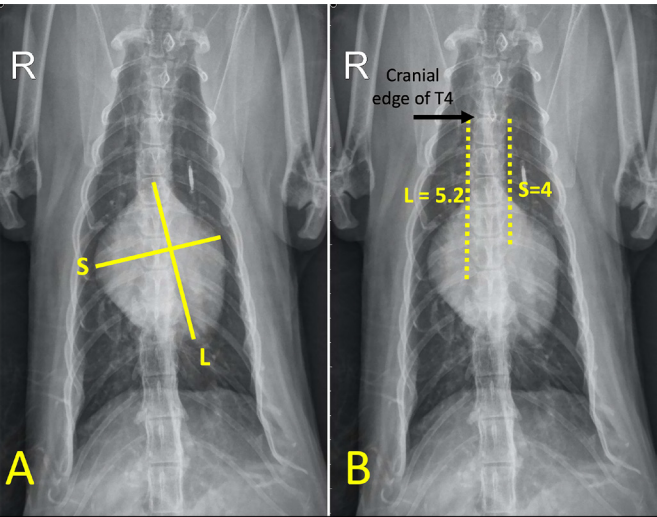


**Figure 2:** VHS measurement in a cat, left lateral view. Measurement of cardiac silhouette in long axis (L) and short axis (S), with comparison of L and S to vertebral body lengths.

# MEASURING VHS IN CATS (VD VIEW)

## Using the ventrodorsal projection:

1. Identify the longest portion of the heart from base to apex (long axis of the heart, L).
2. Identify the widest dimension perpendicular to the long axis (short axis of the heart, S).
3. Identify the 4th thoracic vertebra (T4) from a lateral view, and place 2 lines equal in length to the long and short axis lines at the cranial edge of T4.
4. Determine the length of each line to the nearest 0.1 thoracic vertebra and add L + S to determine VHS.
5. Normal ventrodorsal VHS in a cat is 7.3 to 9.1. A short axis wider than 4 vertebral bodies is highly supportive of atrial enlargement.



**Figure 3:** VHS measurement in a cat, VD view. A: measurement of cardiac silhouette in long axis (L) and short axis (S). B: Comparison of L and S to vertebral body lengths.

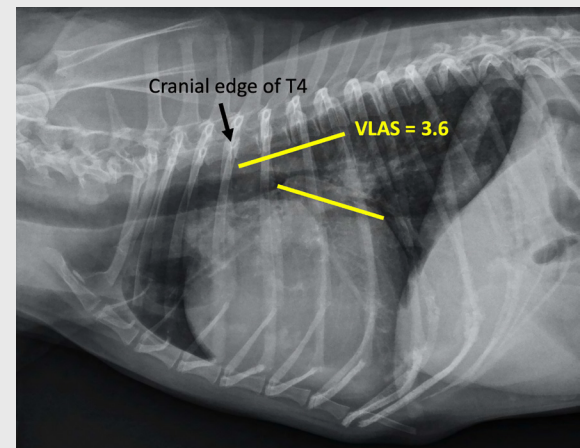
# The value of measuring the Vertebral Left Atrial Size (VLAS) in dogs

With the VLAS measurement spanning the visible left atrium at the caudal dorsal aspect of the cardiac silhouette on the lateral view, the VLAS measurement reflects the general size of both left atrium and left ventricle. This measurement can be used to monitor the size of the left atrium on serial radiographs and can be used to indicate when therapy is indicated in preclinical canine patients. This measurement has not been well-investigated in cats.

*Step-by-step directions for assessment of VLAS in dogs appear in Box 3 and Figure 4.*

## MEASURING VLAS IN DOGS

1. Use a lateral radiograph of the thorax, centered over the heart.
2. Measure the distance from the base of the heart (the center of the ventral margin of the carina) to the most caudal edge of the left atrium where it intersects with the dorsal border of the caudal vena cava.
3. Compare the length of this line to the length of the vertebrae dorsal to the heart, beginning with the cranial edge of the fourth vertebral body on the spine (T4).
4. Count how many vertebral bodies are included along this length to the nearest 0.1 thoracic vertebra. A vertebra consists of a single vertebral body starting at the cranial end-plate and includes the disc space immediately caudal to that vertebra.
5. VLAS is defined as the length of the line expressed in vertebral-body units. If the measurement is greater than 2.5, the dog probably has an enlarged left atrium/ventricle. If the VLAS is greater than 3.0 vertebrae, the likelihood of left atrial/left ventricular enlargement is even higher. The VLAS of normal dogs generally fall below 2.3.



**Figure 4:** VLAS measurement in a dog, left lateral view. Measurement compared to vertebral body lengths.

## Technical aspects of measuring VHS and VLAS

The first step in performing a VHS measurement is to obtain a good quality thoracic radiograph. This can be challenging. The radiograph should be centered over the heart. Films that are centered over the diaphragm or abdomen can foreshorten the thoracic vertebral bodies, thus falsely elevating the VHS. In addition, if the radiographs are not centered over the thorax, it can be hard to see the disc spaces between the vertebral bodies, making it harder to count vertebral bodies

accurately. The patient needs to remain still, and the radiograph should be taken during a deep inspiratory breath. The patient needs to be in a straight lateral position (either right or left). Taking both lateral views can sometimes be helpful if the structures and borders in question are more easily seen on one lateral vs. the other.

Pulmonary pathology is often best seen in the lung opposing the recumbency (left lung in right lateral recumbency, and vice versa). However, I would suggest veterinarians always order the same lateral view(s), because the heart looks a little different on a left lateral versus a right lateral view and the VHS measurement is usually slightly different on the right vs. left lateral. I prefer a three-view study. If you must use a single lateral view, be consistent: don't switch back and forth.

Some people have trouble finding the fourth thoracic vertebral body. The thoracic vertebrae all have a tall spinous process, so I count the spinous processes, starting at first thoracic vertebra (T1), because they are easy to see. After finding the fourth thoracic vertebral spinous process, I follow it ventrally until I reach the body of that vertebra, which tends to be slightly cranial to the dorsal process.

## Limitations

VHS assessment accuracy may be affected by interobserver variability. This means that two people may obtain different VHS values using the same radiographic images. If the VHS is enlarged but no specific chamber enlargement can be identified, this could indicate pericardial effusion or right heart enlargement. Malformations of the thoracic spinal vertebrae (shortened or "butterfly" vertebrae) can result in inaccurate estimations of VHS or VLAS. Excessive pericardial or intrathoracic fat can make accurate identification of the cardiac silhouette more difficult, often leading to overestimation of the heart size.

Some breeds have a wider normal range for the VHS. Unfortunately, these include common breeds that may have breed-related heart disease such as the Cavalier King Charles Spaniel and the boxer. Specific breed tables may need to be consulted for some dog breeds (Table 1).

## Using VHS and VLAS in clinical patients

Assessment of VHS (cats and dogs) and VLAS (dogs) with the breed, age, physical examination (heart murmur), signs of heart failure and other radiographic findings, a veterinarian can treat the dog or cat even if referral to a cardiologist is declined. Radiographs alone can change what an owner and clinician decide to do if the patient cannot receive an echocardiogram. The VHS and VLAS, combined with other radiographic findings (subjective evidence of left atrial dilation, venous distention, typical interstitial/alveolar lung pattern) and other predictors of increased risk of heart failure (breed, age and presence of heart murmur), may allow a tentative diagnosis of heart failure and therapy to stabilize the patient can begin, even if referral is anticipated.

Some recent studies have shown that instituting cardiac medication prior to the onset of heart failure in canine myxomatous mitral valve disease (MMVD) patients with heart enlargement can



significantly prolong the asymptomatic phase of their disease. [See EPIC Study recommendations.](#) In dogs with left apical systolic heart murmurs  $\geq$  grade 3/6, radiographic criteria to identify likely Stage B2 MMVD dogs includes vertebral heart size (VHS)  $\geq$  11.5 or vertebral left atrial size (VLAS)  $\geq$  3 measured on a lateral radiograph. Accurately identifying heart enlargement in these patients and beginning pimobendan therapy can significantly prolong quality and quantity of life.

The rate of change of VHS per month may also be a valuable indicator of the risk of congestive heart failure development. In preclinical MMVD dogs, a change of 0.1 vertebral body/month over 6-12 months indicates a higher risk for development of congestive heart failure, and in the CEG's opinion, is equivalent to Stage B2 for treatment considerations.

Some cardiac patients are euthanized because owners can't afford an echocardiogram, or they are given a negative prognosis. Many owners who decline referral and echocardiography would be able to afford less than \$100 a month for medication, plus thoracic radiographs and screening blood work. With appropriate treatment, a dog or cat with heart disease and secondary CHF can live for more than a year and sometimes two while remaining relatively symptom-free. Many of these patients, despite the need for heart failure medication, will feel well and the owners will be pleased with their quality of life.

---

## FOR MORE INFORMATION:

Buchanan JW. Vertebral scale system to measure heart size in radiographs. *Vet Clin North Am Small Anim Pract.* 2000 Mar;30(2):379-93.

Buchanan JW, Bücheler J. Vertebral scale system to measure canine heart size in radiographs. *J Am Vet Med Assoc.* 1995 Jan 15;206(2):194-9.

Malcolm EL, Visser LC, Phillips KL, Johnson LR. Diagnostic value of vertebral left atrial size as determined from thoracic radiographs for assessment of left atrial size in dogs with myxomatous mitral valve disease. *J Am Vet Med Assoc.* 2018 Oct 15;253(8):1038-1045.

## ADDITIONAL REFERENCES:

Bavegems V, VanCaelenberg A, Duchateau L, Sys SU, Van Bree H, De Rick A. Vertebral heart size ranges specific for whippets. *Vet Radiol Ultrasound.* 2005;46(5):400-403.

Ghadiri A, Avizeh R, Abdo Rasekh A, Yadegari A. Radiographic measurement of vertebral heart size in healthy stray cats. *J Feline Med Surg.* 2008 Feb;10(1):61-5.

Jepsen-Grant K, Pollard RE, Johnson LR. Vertebral heart scores in eight dog breeds. *Vet Radiol Ultrasound.* 2013;54(1):3-8.

Lamb CR, Wikeley H, Boswood A, Pfeier DU. Use of breed-specific ranges for the vertebral heart scale as an aid to the radiographic diagnosis of cardiac disease in dogs. *Vet Rec.* 2001;148(23):707-11.

Litster AL, Buchanan JW. Vertebral scale system to measure heart size in radiographs of cats. *J Am Vet Med Assoc.* 2000;216(2):210-14.

Mikawa S, Nagakawa M, Ogi H, Akabane R, Koyama Y, Sakatani A, Ogawa M, Miyakawa H, Shigemoto J, Tokuriki T, Toda N, Miyagawa Y, Takemura N. Use of vertebral left atrial size for staging of dogs with myxomatous valve disease. *J Vet Cardiol.* 2020 Aug;30:92-99.

Sleeper MM, Roland R, Drobatz KJ. Use of the vertebral heart scale for differentiation of cardiac and noncardiac causes of respiratory distress in cats: 67 cases (2002-2003). *J Am Vet Med Assoc.* 2013 Feb 1;242(3):366-71.

Stepien RL, Rak MB, Blume LM. Use of radiographic measurements to identify dogs with Stage B2 preclinical myxomatous mitral valve disease. *J Am Vet Med Assoc.* 2020 May 15;256(10):1129-1136.

**TABLE 1: COMPILATION OF BREED-SPECIFIC VHS REFERENCE RANGES AND REFERENCES<sup>1</sup>**

Dog Breed	Recumbency	Normal VHS ±SD	Suggested Reference Ranges	Reference
<b>General range for dogs</b>	<b>Left/Right</b>	<b>9.5+0.5</b>	<b>8.7-10.7</b>	<b>Buchanan &amp; Bucheler (1995)</b>
American Pit Bull Terrier	Right	10.9 ±0.4	9.9-11.9	Lahm et al. (2011)
Beagle <sup>2</sup>	Right	10.5, ±0.4	9.5-11.5	Kraetschmer et al. (2008)
Boston Terrier <sup>3</sup>	Right	11.7, ±1.4	8.2-15.2	Jepsen-Grant et al. (2013)
Boxer	Right	11.6, ±0.8	9.6-13.6	Lamb et al. (2002)
Bulldog (English and French) <sup>3</sup>	Right	12.7, ±1.7	8.5-16.9	Jepsen-Grant et al. (2013)
Cavalier King Charles Spaniel	Right	10.6, ±0.5	9.4-11.9	Lamb et al. (2001)
Dachshund	Right	9.7, ±0.5	8.5-11.0	Jepsen-Grant et al. (2013)
Doberman	Right	10.0, ±0.6	8.5-11.5	Lamb et al. (2002)
German Shepherd	Right	9.7, ±0.8	7.7-11.7	Lamb et al. (2001)
Greyhound <sup>2</sup>	Left/Right	10.5, ±0.1	10.25-10.75	Marin et al. (2007)
Labrador Retriever <sup>2</sup>	Right	10.4, ±0.5	9.2-11.7	Jepsen-Grant et al. (2013)
Lhasa Apso	Right	9.6, ±0.8	7.6-11.6	Jepsen-Grant et al. (2013)
Maltese	Right	9.5, ±0.5	8.3-10.8	Baisan & Vulpe (2022)
Miniature Schnauzer	Right	10.9b	9.2-12.5b	Murphy et al. (2024)
Pomeranian	Right	10.5, ±0.9	8.3-12.8	Jepsen-Grant et al. (2013)
Poodle	Right	10.1, ±0.5	8.9-11.4	Fonsecapinto & Iwasaki (2004)
Pug	Right	10.7, ±0.9	8.5-12.9	Jepsen-Grant et al. (2013)
Rottweiler <sup>2</sup>	Right	9.8, ±0.1	9.6-10.1	Marin et al. (2007)
Shih Tzu	Right	9.5, ±0.6	8.0-11.0	Jepsen-Grant et al. (2013)
Whippet <sup>2</sup>	Right	10.8, ±0.6	9.3-12.3	Bavegems et al. (2005)
Yorkshire Terrier	Right	9.8, ±0.5	8.3-11.1	Lamb et al. (2001)

- a. Reference ranges are projected based on mean +/-2.5 standard deviations  
b. Median and reference ranges calculated using Clinical Laboratory Standard Institute methodology

1. Most of the studies referenced are based on small samples. For small sample sizes, mean + 2.5 SD may best reflect the normal reference range. Measured VHS should be evaluated in the context of other clinical data.  
2. Values using left lateral views have also been published.  
3. Reported values for these breeds may be affected by the presence of vertebral anomalies.

**TO LEARN MORE OR SIGN UP  
FOR OUR NEWSLETTER, VISIT  
[cardiaceducationgroup.org](https://cardiaceducationgroup.org)**

