

Dr. Alan Spier,
DVM, PhD, Diplomate ACVIM

Florida Veterinary Specialists, Tampa, Fla.

Reading ECGs



Electrocardiography (ECG) is an important diagnostic tool in the practice of veterinary medicine. Not only does it evaluate the electrical function of the heart, an ECG is also able to give information regarding noncardiac illness. When performing ECGs, it is important to recognize the limitations as well as the benefits of their use in clinical practice. The following discussion will describe ways to acquire an ECG, discuss the approach to rhythm analysis, and provide a review of the common rhythms/arrhythmias seen in veterinary practice.

The most common method of obtaining an ECG is the rhythm strip. In most cases, this type of recording involves the use of a single lead (usually lead II) to evaluate the cardiac rhythm. When recording a lead II rhythm strip, the patient is generally placed in right lateral recumbency, and a positive electrode (usually red) is placed on the back left foot/leg, while a negative electrode (usually white) is placed on the front right foot. A third electrode (either black or green) is used as a ground and

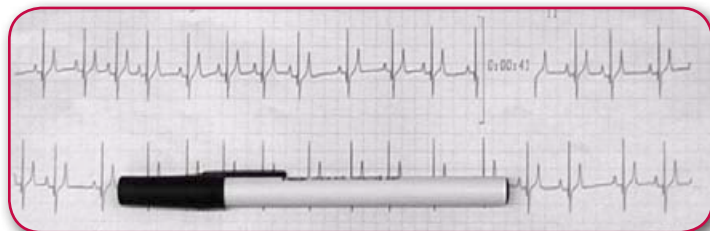
“Not only does it evaluate the electrical function of the heart, an ECG is also able to give information regarding noncardiac illness.”

can be placed anywhere; by convention, black is usually placed on the left front foot/leg, and green is placed on the right rear foot/leg. When using machines that can simultaneously record multiple leads, all electrodes are placed, and the processor within the ECG machine can determine the appropriate combinations to record the frontal leads I, II, III, aVR, aVL and aVF. Other methods for recording an ECG include wireless

transmission to a remote display (telemetry), transtelephonic transmission and ambulatory ECG recordings for extended periods of time (Holter or event monitors).

Regardless of the method of acquisition, the value of an ECG lies in its interpretation. **It is important to realize that an ECG provides only two pieces of information with any degree of reliability: the heart rate and rhythm.** Other information that can be obtained from an ECG tracing includes an assessment of chamber size, axis shifts and fluid accumulation; the interpretation of these abnormalities is more or less inferred, and is therefore less dependable. For these reasons, it is reasonable to begin the analysis of the ECG by calculation of heart rate. Much like obtaining a heart rate from a physical exam, measuring the heart rate from an ECG requires counting the number of normal complexes (p waves for atrial rate, QRS waves for ventricular rate) in a given time period. Depending on the length of an ECG, it is easiest to count either 3 seconds (and multiply by 20) or 6 seconds (and multiply by 10). The length of paper that represents 3 or 6 seconds is dependent on the paper speed. As a convenient rule of thumb I use a length of 150mm (or 30 big boxes). At a paper speed of 25mm/sec, this length represents 6 seconds; at a paper speed of 50mm/sec, this length represents 3 seconds. The other advantage for this method is the fact that a standard Bic Round Stic pen (with the cap ON) is exactly 150mm long. Calculating a heart rate then becomes as easy as putting the pen on the ECG, counting complexes and multiplying by the appropriate factor.

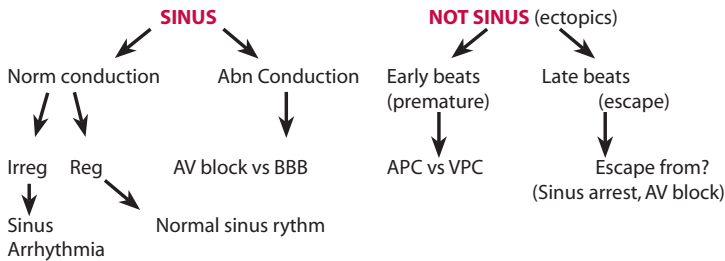
In this example, there are 9 QRS complexes in the length of the Bic pen. That means in 150mm, this dog's heart beat 9 times. If the paper speed is 50mm/sec, the 150mm would represent 3 sec ($150 \div 50 = 3$). Therefore the heart rate would be 9×20 , or 180bpm. In reality, the paper speed is 25mm/sec, making the 150mm pen represent 6 sec ($150 \div 25 = 6$). Therefore the heart rate is 9×10 , or 90bpm.



Once the heart rate is obtained, the next step is to determine whether the heart rate is slow, fast or normal. It can be challenging to define a normal rate given the potential range of heart rates that could be considered normal (for a dog, 35 is normal if sleeping, but 180-200 could be normal if exercising). Therefore the term “reasonable” may be preferable to allow for flexibility of interpretation. The following table represents reasonable guidelines regarding heart rates in dogs and cats:

	Dog	Cat
Fast	>160	>220
Slow	<70	<140

If the heart rate is slow, the possible explanations include abnormalities with sinus node (sinus arrest, sinus bradycardia) or alterations in AV nodal conduction (AV block, usually 2nd or 3rd degree). If the heart rate is fast, options are limited to either a sinus tachycardia, supraventricular tachyarrhythmias (atrial or junctional) or ventricular tachycardia. If the heart rate is reasonable, then one must determine if it is entirely sinus in origin, or if there are premature beats (APCs/VPCs) or escape beats/pauses. The following algorithm can be useful when the heart rate is reasonable:



Another useful approach to analyzing an ECG is to consider arrhythmias as either abnormalities in impulse formation or disorders in impulse conduction. Normally, the electrical activation of the heart originates in the SA node (primary pacemaker), but secondary pacemakers do exist, and can be responsible for impulse generation if higher pacemakers fail. These secondary pacemakers include the AV node or Purkinje fibers within the ventricles; initiation of impulses from these locations is responsible for escape beats. Impulses can also be formed abnormally by tissue that is not normally capable of pacemaking activity. These tissues generally include the working muscle of the atria and ventricles, and are responsible for premature beats (APCs and VPCs, respectively). Abnormalities in impulse conduction also occur, and are generally limited to alteration in conduction through the AV node (AV block) or conduction across the

bundle branches (bundle branch block). While there are other examples of conduction disturbances, they are comparatively rare and will not be discussed. The following represents a list of arrhythmias seen in veterinary medicine.

Rhythm Origins

SINUS

- Sinus rhythm
- Sinus arrhythmia (with or without wandering pacemaker)
- Sinus tachycardia
- Sinus bradycardia
- Sinus arrest

ATRIAL

- Atrial premature complexes (APCs)
- Atrial tachycardia
- Atrial flutter
- Atrial fibrillation
- Atrial standstill

VENTRICULAR

- Ventricular premature complexes (VPCs)
- Ventricular tachycardia
- Ventricular flutter
- Ventricular fibrillation
- Asystole/flatline

Conduction Disturbances

AV BLOCK

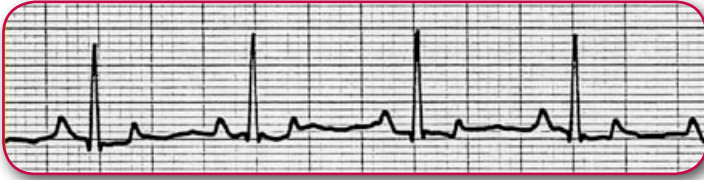- 1st degree
- 2nd degree
- 3rd degree

BUNDLE BRANCH BLOCK

- Left BBB
- Right BBB

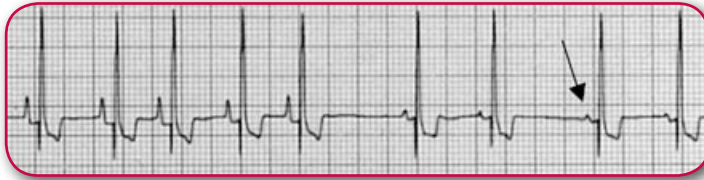“Another useful approach to analyzing an ECG is to consider arrhythmias as either abnormalities in impulse formation or disorders in impulse conduction.”

Sinus Rhythms



ECG 1 Normal Sinus Rhythm

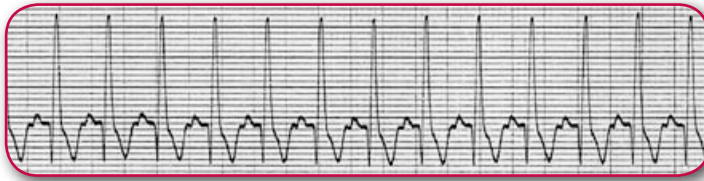
HR=100, reasonable rate, sinus in origin, normal conduction, regular rhythm



ECG 2 Sinus Arrhythmia

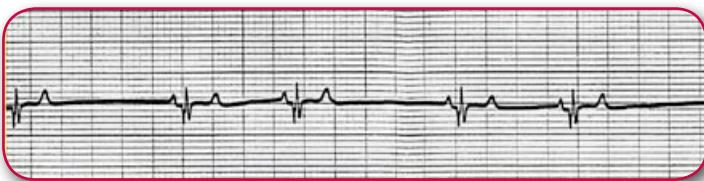
HR=100, reasonable rate, sinus in origin, normal conduction, irregular rhythm

Note variation in p wave morphology—wandering pacemaker



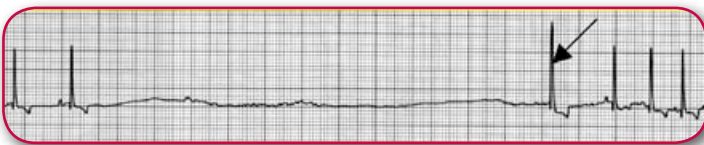
ECG 3 Sinus Tachycardia

HR=200, fast, narrow complex, p wave for every QRS



ECG 4 Sinus Bradycardia

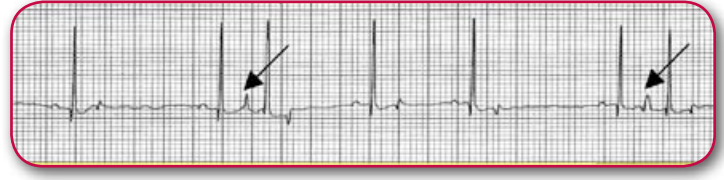HR=60, slow, sinus in origin, no blocked p waves, no periods of arrest



ECG 5 Sinus Arrest

HR=30 (average), slow, sinus beats with 5-second pause, escape beat after pause

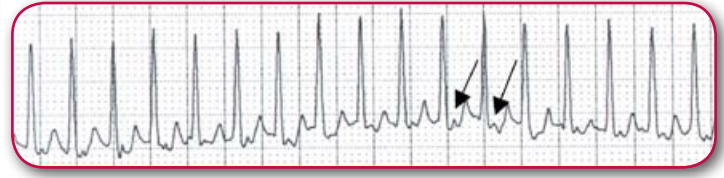
Atrial Rhythms



ECG 6 Atrial Premature Complex

HR=80, reasonable rate, not all sinus, premature beats with narrow QRS complex

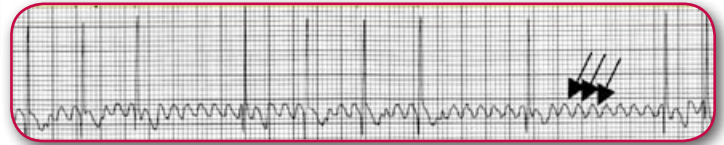Note p wave of APC superimposed on previous T wave of normal complex



ECG 7 Atrial Tachycardia

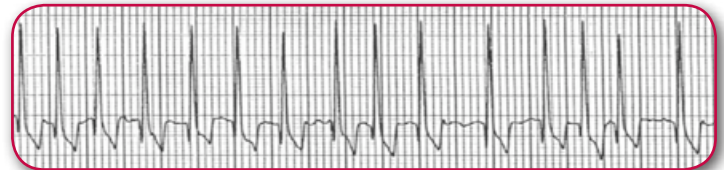
HR=260, fast, narrow complexes (not V-tach), no obvious p waves (may be buried)

Rate is too fast for sinus; likely supraventricular (not irregular like atrial fibrillation)



ECG 8 Atrial Flutter

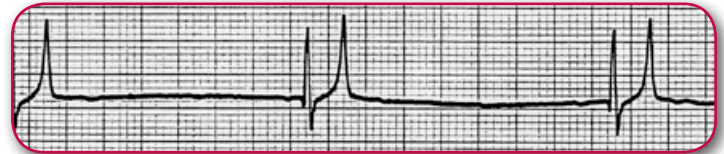QRS rate=100, narrow complexes, saw-toothed P-waves at rate of 500 bpm; QRS rate likely slow due to therapy



ECG 9 Atrial Fibrillation

HR=240, fast, narrow complexes (not V-tach), no p waves, very irregular

Classic appearance including fast rate, no p waves, irregular rhythm

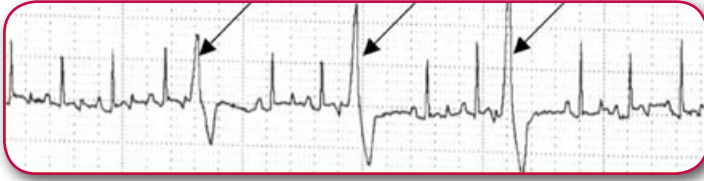

ECG 10 Atrial Standstill

HR=40, slow rate, no p waves, regular rhythm, tented T waves suggesting hyperkalemia

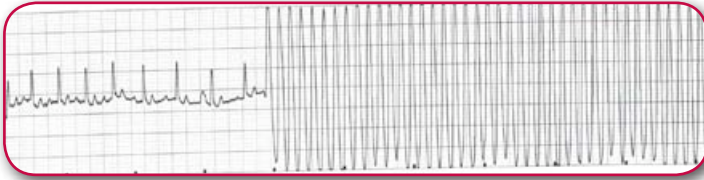
Note that atrial standstill is technically a sinus bradycardia with paralyzed atria (thus no P wave)

Ventricular Rhythms



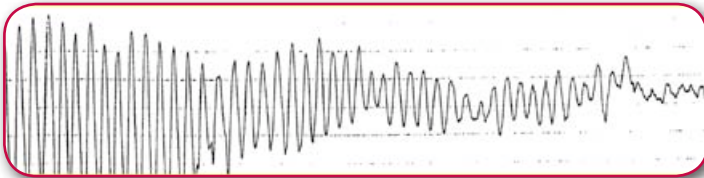
ECG 11 Ventricular Premature Complex

HR=140, reasonable rate, not all sinus, premature beats with wide QRS complex



ECG 12 Ventricular Tachycardia

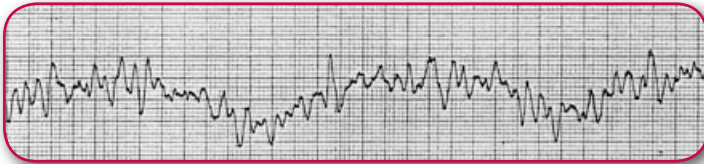
HR=initially 140, then rapid rate at 400 with wide complexes



ECG 13 Ventricular Flutter

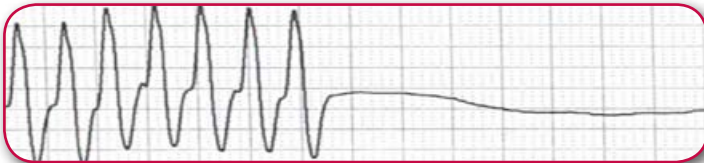QRS rate=360 at first, then degeneration into ventricular fibrillation

Note loss of QRS morphology as transforms from flutter to fibrillation



ECG 14 Ventricular Fibrillation

Note inability to count complexes due to lack of QRS morphology

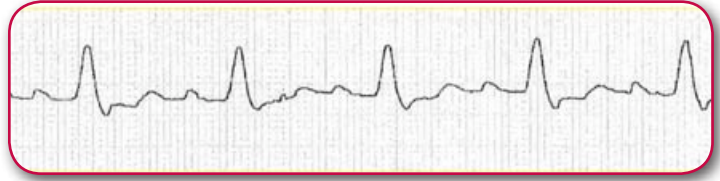


ECG 15 Asystole

Initial HR=240 (v-tach), then abruptly terminates into asystole

“Regardless of the method of acquisition, ECG lies in its interpretation.”

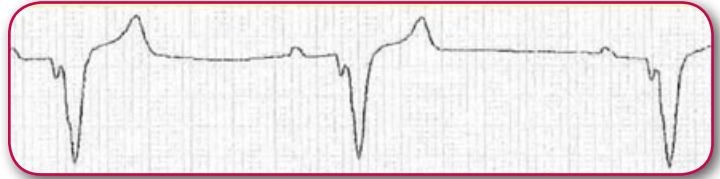
Conduction Abnormalities



ECG 16 Left Bundle Branch Block

HR=140, reasonable rate, all sinus, abnormally conducted (QRS morphology is abnormal)

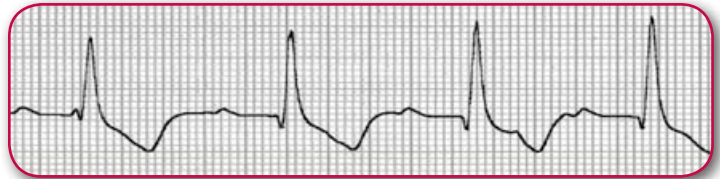
Note sinus beats with wide complexes and normal axis implies LBBB



ECG 17 Right Bundle Branch Block

HR=100, reasonable rate, all sinus, abnormally conducted (QRS morphology is abnormal)

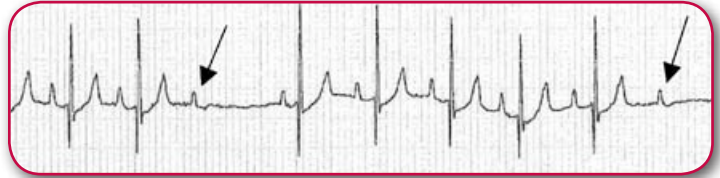
Note sinus beats with wide complexes and right axis implies RBBB



ECG 18 1st degree AV block

HR=120, reasonable rate, all sinus, abnormally conducted (PR interval is long)

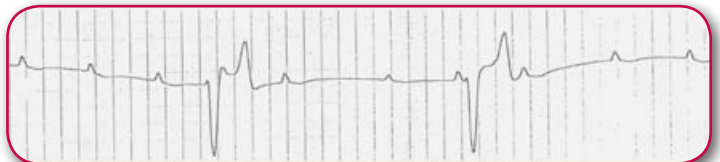Note with 1st degree AV block, all p waves are conducted (just prolonged)



ECG 19 2nd degree AV block

HR=110, reasonable rate, all sinus, abnormally conducted (occasional dropped P wave)

Note that with 2nd degree AV block some P waves are conducted, others are dropped



ECG 20 3rd degree AV Block

QRS rate=30, slow, p wave rate 110, no clear p-QRS relationship
Note QRS complexes are wide and bizarre-ventricular escape from complete AV block